

# Poultry Fecal Analysis

The color and texture of chicken fecal material can indicate the health status of the animal's digestive tract. This poster includes examples of abnormal droppings, as well as possible conditions to rule out.

*This poster is only a summary and is not a completely inclusive list. Fecal changes may be caused by a multitude of factors. If a problem is suspected, please contact your veterinarian.*

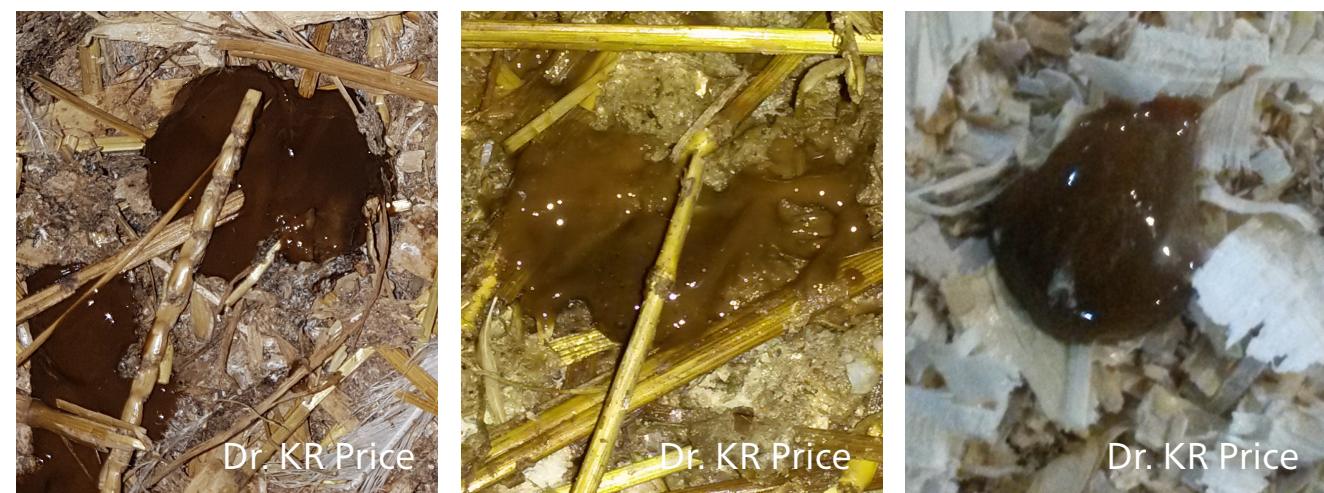## NORMAL FECAL DROPPINGS

### INTESTINAL DROPPINGS



Usually voided as digestive waste with white uric acid crystals on the outer surface.

### CECAL DROPPINGS



Normally expelled two or three times a day (or once in every 8 to 10 droppings). They look pasty, smell worse than intestinal droppings and are often light to dark brown in color.

## ABNORMAL CECAL DROPPINGS

### FOAMY



#### Caramel, light brown, brown

Light to dark brown, watery and/or foamy

Conditions to rule out: Viral infection (e.g., adenovirus, reovirus), dietary changes, feed ingredients that were not digested or absorbed correctly (e.g., high crude protein), bacterial infection (e.g., necrotic enteritis), parasitic infection, dysbacteriosis

#### Yellow

Yellow-colored, may be blood-stained and/or foamy

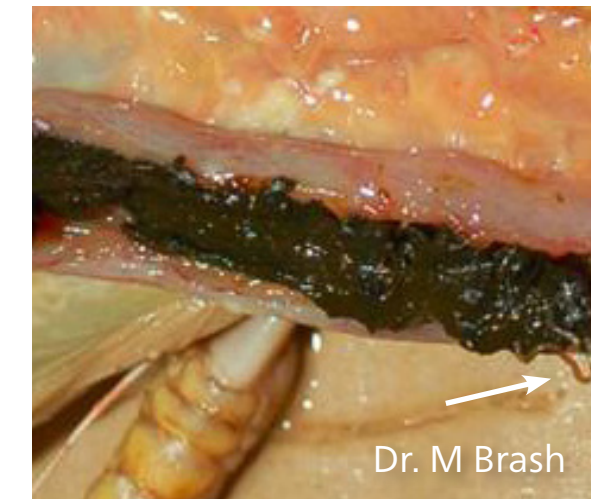
Conditions to rule out: Blackhead (*Histomonas meleagridis*), viral infection, dietary changes, bacterial infection, microbial imbalance

#### Red

Bloody, light to dark red, can be sticky or loose

Conditions to rule out: Cecal coccidiosis (*Eimeria tenella* or *Eimeria brunetti*)

### WORMS



#### Cecal worms

- Small (<1 cm), thin worms that can take on the color of the dropping
- Dropping appears light to dark in color
- Dropping has loose to sticky texture, appears almost bumpy with worms

Conditions to rule out: Cecal worm (*Heterakis gallinae*)

## ABNORMAL INTESTINAL DROPPINGS

### LOOSE DROPPINGS



#### Mucus

- Medium to high mucus content that appears sticky, shiny
- This can be the intestinal mucosal lining falling off normally (low mucus content) or abnormally (medium to high mucus content) and being excreted
- White urates may be found

Conditions to rule out:

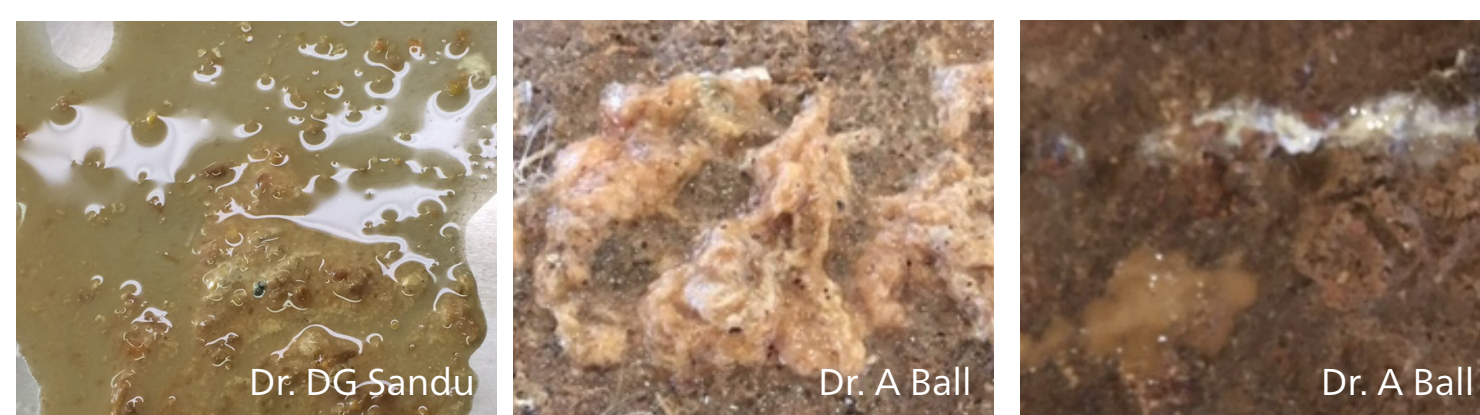Gastrointestinal tract disease (e.g., necrotic enteritis (*Clostridium perfringens*), *Salmonella typhimurium*, coccidia, ascarids, enteric viruses (like torovirus), histomoniasis.

Dysbacteriosis (e.g., microbial imbalances).

Mycotoxins (e.g., aflatoxin, fumonisins, sterigmatocystin, ochratoxin and undefined toxins of *Penicillium*).

Toxic injury (e.g., oxidized/rancid fats, biogenic amines).

Feed management (e.g., extended feed withdrawal, dropping just after dark period).



#### More Fluid

- Clear, watery droppings
- Some normal intestinal droppings with notably more fluid around the feces
- In higher-challenge cases, there may only be watery feces
- White urates may or may not be found

Conditions to rule out: Malabsorption syndrome.

Viruses (e.g., reovirus, rotaviruses, astroviruses, enteroviruses, mycotoxins).

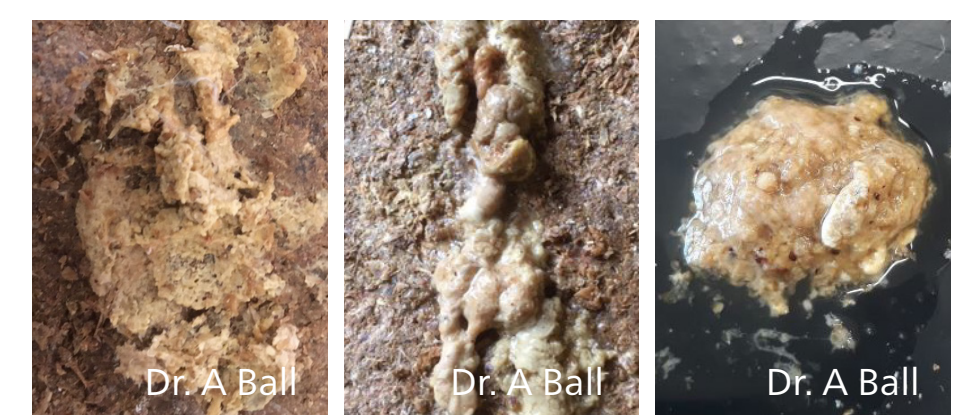Intestinal challenges (e.g., viral, bacterial, parasitic).

Dietary changes (e.g., high in salt, excess levels of magnesium (carbonate, sulfate, and oxide forms), non-starch carbohydrates (e.g., raffinose in soybean meal, lactose in whey, pentosans in small grains, sucrose).

Behavioral (e.g., increased water consumption).

Physical or physiological stress (e.g., vaccination, environmental temperature, drastic change in feed formulations).

### COARSE TEXTURE

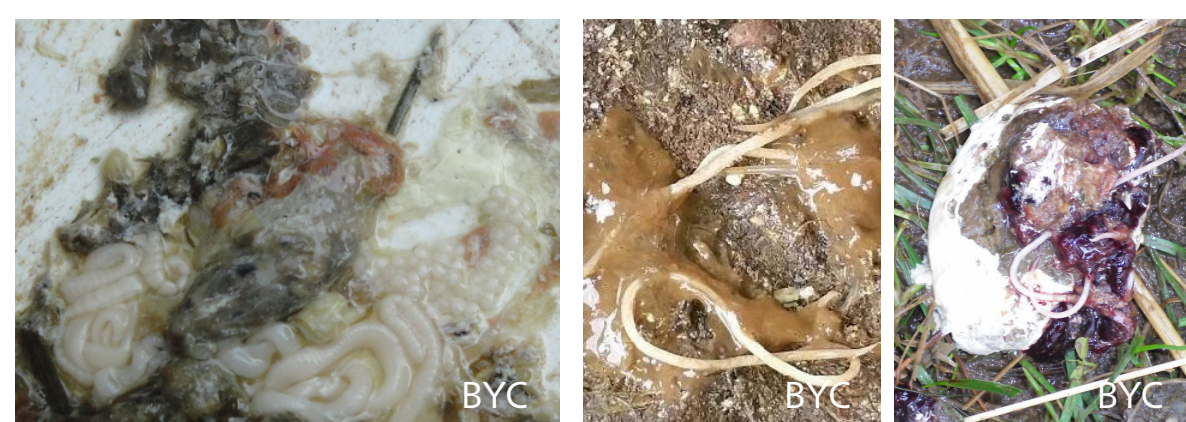

#### Undigested Feed

Undigested feed can be seen in the feces.

Conditions to rule out: Gizzard erosion, viral/bacterial/parasitic infection, malabsorption syndrome, mycotoxins, stressors, dietary changes, rancid fats, poor feed quality, particle size of grinded grains

## PARASITES/ WORMS



#### Tapeworms

Small white segments, ball-looking structures and/or long ribbon-shaped worms may be found. The intestinal feces may be normally formed or watery/mucus-like.

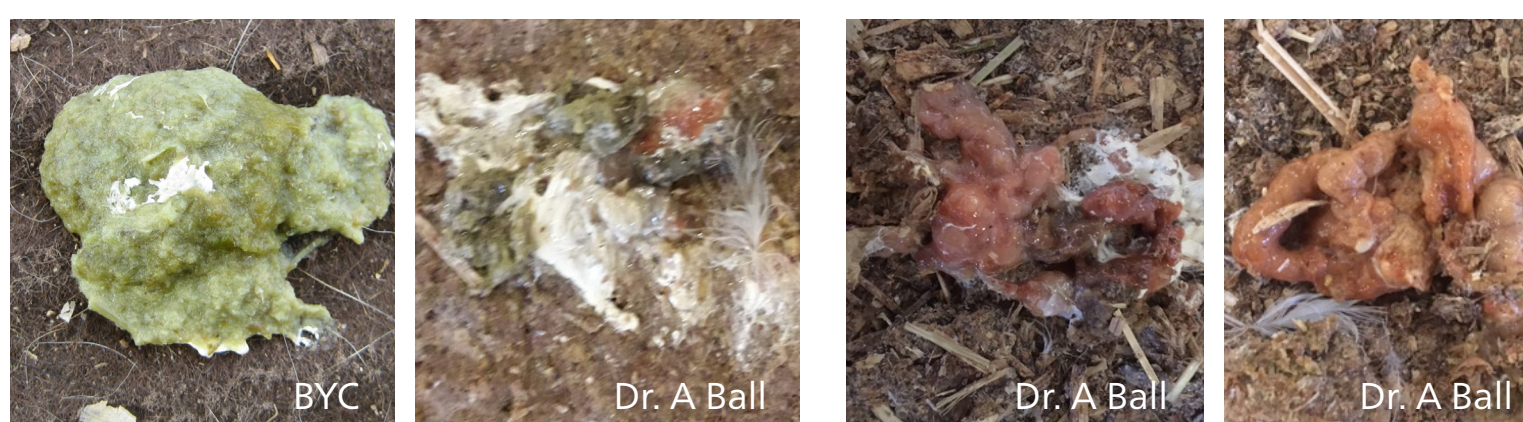Conditions to rule out: Tapeworms (e.g., *Raillientina cesticillus*, *Choanotenia infundibulum*), de-worming strategies

#### Roundworms

Medium to long round worm-like worms may be found in the intestinal feces. The color of the worm may be white to off-white. If severely infected, the feces may be watery.

Conditions to rule out: Roundworms (*Ascarids*), de-worming strategies

## CHANGES IN COLOR



#### Green

Greenish droppings combined with very little fecal matter and condensed urates, which contains little mucus around it.

Conditions to rule out:

Systemic disease (e.g., *E. coli* infection, Newcastle disease, infectious bronchitis, leucocytozoonosis, coryza, avian influenza, lymphoid leukosis). Liver malfunction/abnormal bile secretion (due to mycotoxins, fatty liver, heavy metals).

Bird not eating (due to infection or acute stressors, such as vaccination, medication, environmental temperature, sudden change in environmental conditions).

#### Orange/red

Conditions to rule out: This color may be due to an increased level of intestinal cell sloughing and/or mucus. Check mucus section.

#### White

**Polyuric dropping**  
Contains large amounts of white urates in the excreta. Often mixed with brown droppings.

**White urates**  
In clinical cases, only the white urates are being passed.

Conditions to rule out: Kidney disease, viral infections (e.g., infectious bronchitis) or bacterial infections.

Immune disease (e.g., infectious bursal disease, lymphoid leukosis).

Moldy ingredients (e.g., mycotoxins (like aflatoxin, ochratoxin).

Drugs (e.g., sulfa, gentamycin) have been over-used.

Heavy metals (e.g., lead) are not digested and absorbed.

Dietary changes (e.g., combination of high calcium levels, high vitamin D, low vitamin A and high dietary protein in the diets of older chickens (e.g., layers > 60 weeks old.)

Behavioral changes (e.g., excitement, stress, decreased water intake).

Other diseases: (e.g., worms, coccidiosis, toxoplasmosis).